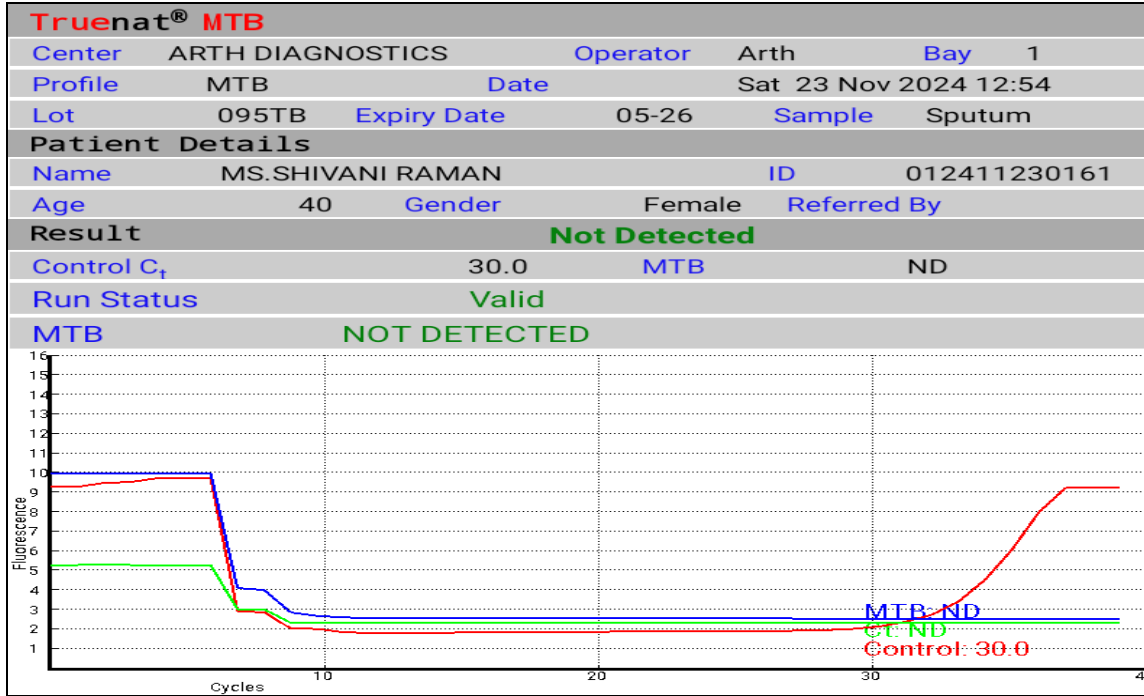


Patient Name : MS. SHIVANI RAMAN
Age & Sex : 40 Years / F
Ref. Doctor :

Received on : 23/11/2024
Reported on : 23/11/2024
Serial No : 012411230161



This report is for the perusal of doctor only. Not for medico legal cases. Clinical correlation is essential. Please contact us in case of unexpected result.