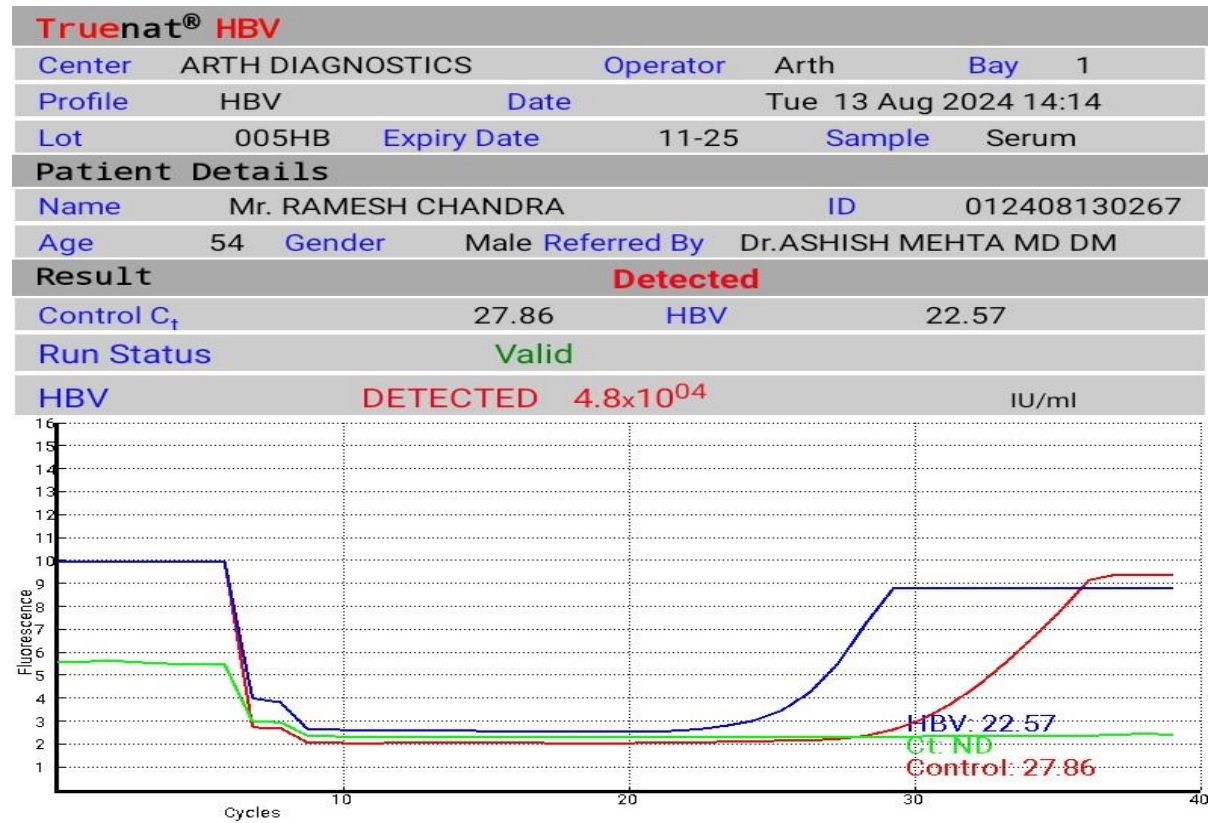


Patient Name : **Mr. RAMESH CHANDRA**
Age & Sex : 54Years / M
Ref. Doctor : Dr. ASHISH MEHTA MD,DM(Gastro.)

Received on : 13/08/2024
Reported on : 13/08/2024
Serial No : **012408130267**



This report is for the perusal of doctor only. Not for medico legal cases. Clinical correlation is essential. Please contact us in case of unexpected result.